

ORIGINAL RESEARCH

Open Access



Evaluation of double-folded meatal-based flap (modified Mathieu) in redo circumcised distal penile hypospadias: a prospective multicenter study

Salah Nagla¹, Mohammed Radwan¹, Mohamed Alhefnawy², Ahmed Ghaith^{1*}, Ayman M. Hagrass¹, Mohammed Shalaby³, Mohammed Awad³, Mohamed Ahmed Negm⁴ and Samir Elgamal¹

Abstract

Background: Sometimes it becomes a dilemma to repair a failed circumcised distal penile hypospadias with partial or complete wound dehiscence. In many of these cases, redo operations need a graft or a flap. The aim of this study is to evaluate the double-folded meatal-based flap in redo circumcised hypospadias with shallow urethral plate and a small glans penis.

Results: From September 2015 to August 2018, we prospectively studied the double-folded meatal-based flap in 56 failed circumcised distal hypospadias without penile curvature with shallow urethral plate and a small glans penis. Distally folded Mathieu flap was done. Forty-seven cases only had completed the study. We had 19 patients with distal penile hypospadias, 19 with sub-coronal hypospadias, and 9 with coronal hypospadias. Median operative time was 50 (range 40–80 min). The median length of the double-folded flap was 14 (range 10–18 mm). The median follow-up was 12 (range 1–33 months). The success of the operation means that there is an absence of any complications. Our success rate was 73%. We had 8 patients with meatal retraction, one fistula, and one patient with wound disruption. Only 3 patients (6.4%) needed re-operation: one case with meatal retraction, another with fistula, and a third with complete wound disruption.

Conclusion: Distally folded meatal-based flap is an additional option in redo circumcised hypospadias with shallow urethral plate, small glans penis, and pliable anterior penile skin with a considerable high percent of meatal recession.

Keywords: Distal hypospadias, Meatal flap, Urethral plate

1 Background

There are many surgical procedures for hypospadias repair, but still there is no gold standard operation for all cases of hypospadias [1]. Many factors may predispose to the failure of distal hypospadias repair including urethral plate characteristics and glans condition [2]. Mathieu technique (perimeatal-based flap urethroplasty procedure) is one of the most popular and old techniques for

hypospadias repair, and its complications mainly consist of urethrocutaneous fistula and meatal retraction [3, 4]. Snodgrass et al. [5] have assumed a simple algorithm to solve problems in the repair of the failed distal hypospadias. But, to repair a failed distal hypospadias with unhealthy urethral plate, it needs a graft or a flap in this algorithm. This necessitates an operation to the repair which may even end with another failure. Moreover, the small glans is one of major risk factors for failure in the hypospadias repair [6]. For that, a small glans should be augmented, especially in the redo hypospadias, to decrease the failure rate. In our study, we evaluate the

*Correspondence: dr_ahmedfayez@yahoo.com

¹ Urology Department, Tanta University, Tanta, Egypt

Full list of author information is available at the end of the article

folded meatal-based flap (modified Mathieu) in the repair of failed circumcised hypospadias with shallow urethral plate and a small glans penis.

2 Methods

We prospectively evaluated the distally folded meatal-based flap in failed distal hypospadias repair from September 2015 to August 2018 in our urology and pediatric surgery departments in Egypt. Sixty-five patients were enrolled in our study. Our patients were circumcised distal hypospadias without penile curvature with unhealthy urethral plate and a small glans penis. Only 47 patients completed the study and 9 skipped the follow-up.

Inclusion criteria

- Failed circumcised (most of the prepuce was removed) distal penile hypospadias,
- Shallow but not scarred urethral plate,
- Available redundant healthy ventral penile skin proximal to the meatus,
- Small glans penis which was less than 14 mm in the maximum transverse diameter.

Exclusion criteria

- Deep urethral plate,
- Penile curvature that required complete penile degloving,
- Glandular hypospadias.

2.1 Operative steps

A midline fixing suture was taken at the glans (Fig. 1). We started the procedure by measuring the length of the urethral plate and the length of the glans, from the

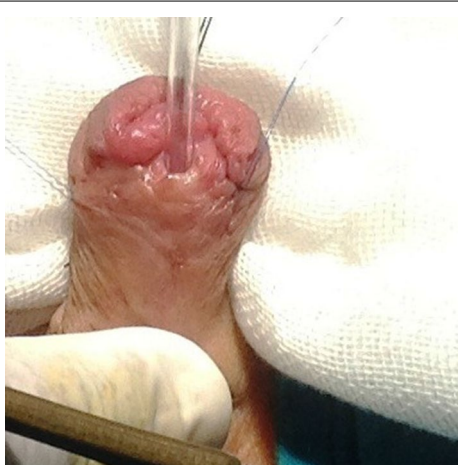

Fig. 1 Redo distal penile hypospadias with small glans penis with most of the prepuce was lost in the previous operations

urethral knob to the corona. The length of the needed ventral flap was equal to the sum of the urethral plate plus the ventral length of the glans (Fig. 2). We fashioned a meatal-based U-shaped incision toward the penile root. Thereafter, the limbs of this incision extended distally around the preserved the urethral plate to the urethral knob. Distal and lateral to the incision, we separated the penile skin from the dartos fascia that was left attached to the flap (Fig. 3). The proximal dissection was done till the flap was free upward. Deep glanular wings were then created to decrease glans tension when they are sutured to the reflected part of the flap. The flap was then taken upwards to assure that the flap would cover the urethra and the reflected distal

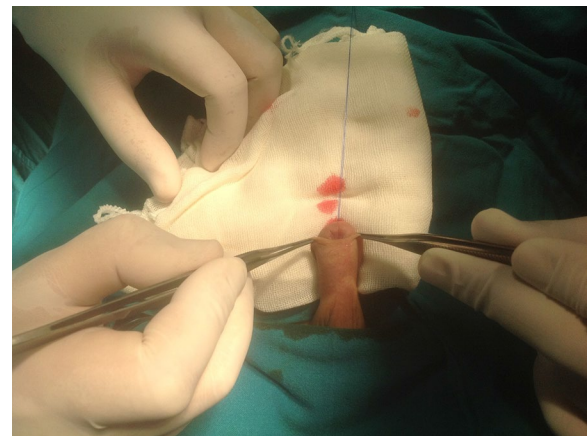


Fig. 2 Ensuring the flap will be of adequate length without inducing penile curvature

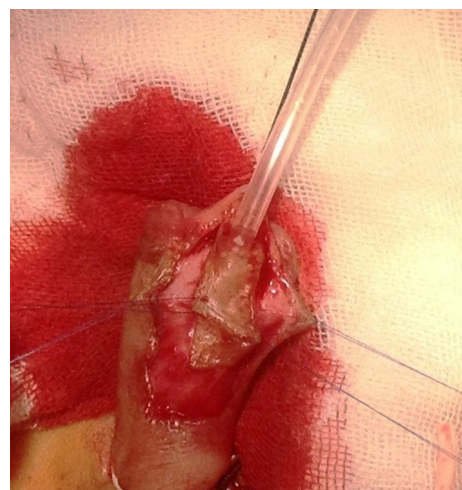

Fig. 3 Fashioning the meatal-based flap and extending the incision till it reaches the urethral knob

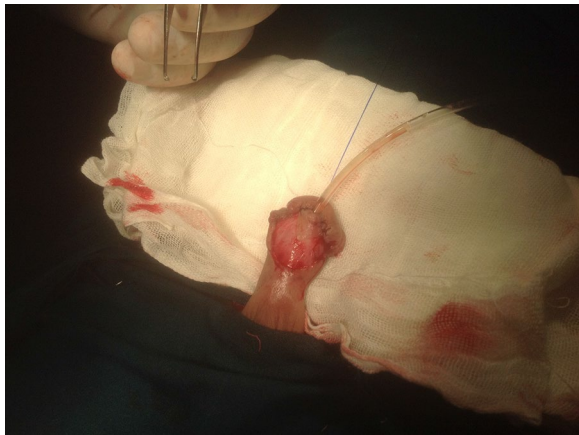

Fig. 4 Covering the urethral plate with the first part of the flap

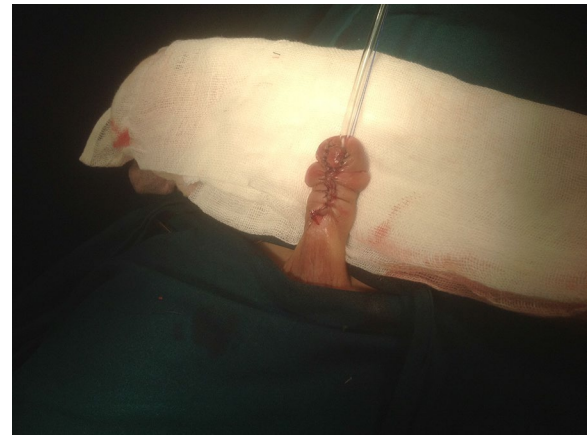

Fig. 6 Skin closure at the midline after completing the procedure

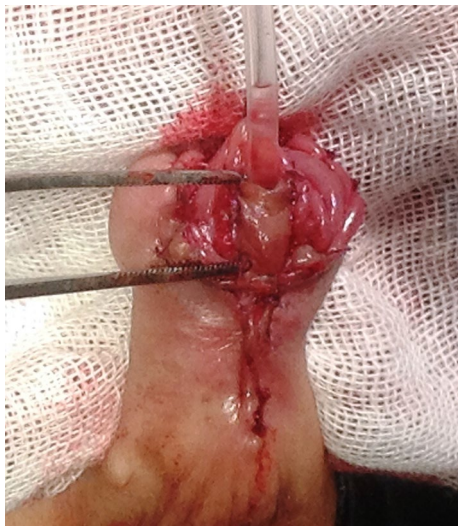

Fig. 5 The remaining part of the flap bridges the defect of the glans penis and prepared to be sutured to the sides of the glans edges

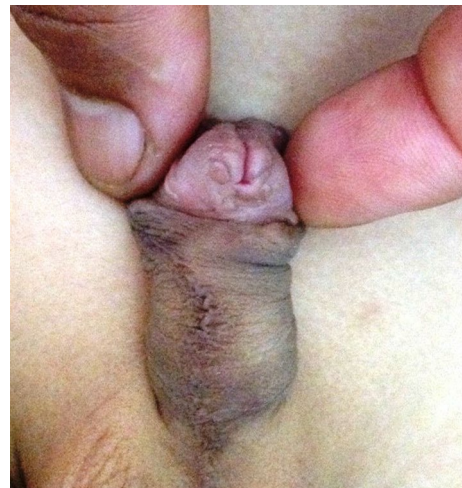

Fig. 7 At 6-month follow-up

part of the flap would bridge the ventral defect of the glans penis without creating penile curvature. Vicryl 6/0 sutures were used to evert the flap upwards to the edges of the urethral plate. The sutures were taken in a subcuticular fashion on the two sides till the urethral knop (Fig. 4). At that time, the urethra was covered with part of the harvested meatal-based flap and continued to the level of the urethral knop of the glans penis. The remaining part of the flap was everted backward like an apron, and each side of the flap was sutured to the ipsilateral side of the glans using 6/0 Vicryl in a continuous subcuticular manner (Fig. 5). Thereafter, the lateral skin was approximated at the midline ventrally (Fig. 6). An 8 Fr. feeding tube was fixed using the midline glans

suture. A simple gauze dressing was applied to dress the penis after completing the surgery. We used a double diaper technique. All patients were discharged at the same day. The dressing was removed after 2 days, and the urethral catheter was removed 5 days after that. The follow-up was scheduled at 2 weeks, 3 months, 6 months (Fig. 7), and yearly thereafter for 2 years at least, or if there were any complications. In the follow-up visits, urethral calibration using 8 French catheters was done to all patients. Examination of the meatus configuration and penile skin for any urethrocutaneous fistula was mandatory. Recording of the voiding pattern by the parents before the follow-up visits was achieved in most of the cases to exclude any penile curvature. The primary outcome was the urethrocutaneous fistula.

The secondary outcomes were any other complications at the urethral meatus, urethra, skin, and penile curvature.

2.2 Statistical analysis

It was done using SPSS version 18, USA. The statistical tests used were median, range and 25 and 75 percentile for the nonparametric data.

3 Results

Forty-seven cases only had completed the study. The median age of the subjects was 48 months (range 23–97 months). The median age of the patients at the earlier repair was 37 (range 12–88 months), and the median number of earlier repairs was 2 (range 1–3). We had 19 patients with distal penile hypospadias, 19 with sub-coronal hypospadias and 9 with coronal hypospadias. Median glans width was 11 (range 9–13 mm), and the median urethral plate length was 10 (range 5–13 mm). Median operative time was 50 (range 40–80 min). Dressing was removed 48 h after surgery, and the median length of catheter stay was 7 days (5–8 days). The median length of the double-folded flap was 14 (range 10–18 mm). The median follow-up was 12 (range 1–33 months). The success of our operation means the absence of any complications. We had eight patients with meatal retraction, one fistula and one patient with wound disruption. Only three patients (6.4%) needed re-operation: one case with meatal retraction, another with fistula, and a third with complete disruption. Our success rate was 73%.

4 Discussion

The chance of another failure in the redo hypospadias is highly present. The shallow urethral plate, a small glans penis, and earlier circumcision augment this probability. Several techniques have been reported to redo a failed hypospadias, e.g., the para-meatal flap, Snodgrass urethroplasty, and free grafts. These cases may need a staged repair according to the characters of the urethral plate, glans size, and penile curvature, but it may end with an unfavorable outcome [5, 7]. The number of the earlier operations is added to the risks of failure in hypospadias repair. This may be the result of the short distance to meatal opening, a higher chance of ascending infection, hematoma, and with more difficulties with immobilization of the free grafts [8]. Glans size is important to the success of the repair. Snodgrass et al. [5] argues that the deep glandular wings help to overcome the small glans size. Testosterone intake could augment the penile glans size. Yet, for the redo hypospadias Snodgrass et al. [6] showed that the risk for glans dehiscence is increased subsequently. In the same study, although glans dehiscence was present in 4% of distal penile hypospadias, it

occurred in 14% in the redo cases and the risk of glans dehiscence is increased by 4.7-fold in the redo cases. Hypospadiologists do not like using skin augmentation of the glans penis for cosmetic reasons. However, this may be allowed in difficult situations of small or scarred glans [9, 10]. Moreover, we augment our efforts to decrease the incidence of recurrence in the redo hypospadias. In this study, we applied a modified Mathieu urethroplasty for failed distal penile hypospadias with a small glans, unhealthy urethral plate, and without penile curvature. The flap would cover the urethral plate; at the same time, the distally folded part of the flap could augment the small glans. Elsayed et al. [9] described a similar technique using a folded preputial flap in the redo non-circumcised hypospadias with small glans and shallow urethral plate. Of their operated 36 cases, they had two urethrocutaneous fistulae; one of them was closed spontaneously. This high success rate may be attributed to the minimal dissection in the previous surgeries which left the prepuce intact. Our cases were circumcised, so we could not apply this technique. The tubularized incised plate (TIP) is the commonest procedure for the primary repair of distal hypospadias. But it has drawbacks in the small and/or the shallow urethral plate [5, 11]. In the present study, patients had shallow urethral plate where TIP was not an ideal option for them. Most of our cases were referred from other centers, and most of the earlier reconstructions were not documented to us. The reported success rate for Mathieu technique exceeds 90% in the primary repair with special precautions and in the hands of expert surgeon [12]. The folded Mathieu has been described by Nezami et al. [13] for the primary repair of distal hypospadias with small glans. They operated 33 out of 54 studied patients using this technique, and follow-up was 20 months. In this group, they had one urethral fistula and no urethral break down or necrosis with overall 97% success rate. They showed better results with this technique than Snodgrass technique in the patients with shallow urethral groove and small glans penis reflecting the fruitfulness of using such technique. We think that the application of this technique would be wiser in the redo distal hypospadias with a small glans penis and shallow urethral plate. Our overall success rate was 73%. And if we excluded the cases of mild meatal recession which did not need further operations, our rate of success would be 93.6%, which we think is acceptable for cases of redo distal hypospadias with unfavorable glans penis and urethral plate. Many modifications have been reported to decrease complications of Mathieu repair [14]. We used the modified sub-epithelial dartos preservation technique to preserve the blood supply of the flap. Also, it decreases the magnitude of dissection in the scarred tissues from multiple earlier operations [15].

Urinary diversion after Mathieu urethroplasty has been a matter of debate. Hakim et al. [16] reported similar results for stented versus non-stented repair. Buson et al. [17] reported an increased incidence of adverse events following non-stented Mathieu repair. Postoperative diversion has been used in most of the literature for the salvage of Mathieu urethroplasty [18]. But, we still need larger prospective studies to test the salvage of Mathieu urethroplasty without diversion [19]. In the present study, we used urethral stenting in all cases. Operative time for this procedure was no longer than the time reported for TIP because we did not need complete degloving nor dartos flap harvesting. We had meatal retraction, urethrocutaneous fistula, and wound disruption in 8 (17.0%), 1 (2%) and 1 (2%) patients, respectively. Our overall success rate was 73%, which was comparable to the result of redo TIP urethroplasty by Snodgrass et al. [5, 20]. At the same time, if we excluded the cases of meatal recession, which did not need further operations, our rate of success was 93.6%. To our knowledge, this technique was described only by Nezami et al. [13] in their comparative study to repair the primary hypospadias. Our study used the same technique prospectively in the redo circumcised distal penile hypospadias with small glans penis in the presence of a shallow urethral plate. We also used the modification of sub-epithelial dartos preservation to increase the vitality of the ventral flap aiming at increasing the success rate of this technique. Our study showed that the folded Mathieu technique is feasible for redo distal hypospadias because it has low complications and overall good outcomes.

4.1 Limitations of the study

In this study, we had short follow-up periods. For this reason, long-term studies are needed. Also, further prospective studies with larger numbers of patients and an adequate assessment scoring are needed to strengthen our findings.

5 Conclusion

The folded Mathieu flap procedure carries a low overall complications rate and improves the functional outcomes. This procedure can be done to repair the failed distal hypospadias with shallow urethral plate and small glans.

5.1 Availability of data and materials

The datasets used and/or analyzed during the current study are available from the corresponding author on reasonable request.

Abbreviations

SPSS: Statistical Package for the Social Sciences; TIP: Tubularized incised plate; USA: United State of America.

Acknowledgements

Not applicable.

Authors' contributions

SN, MS, MA, MAN, and MAA had full access to all the data in the study and took responsibility for the integrity of the data and the accuracy of the data analysis. *Study concept and design* were contributed by SN, MR, AMH, and SE. *Acquisition of data* was contributed by SN, MAA, MS, MA, and MAN. *Analysis and interpretation of data* were contributed by SN, MR, MAA, AG, AMH. *Drafting of the manuscript* was contributed by Mohamed Alhefnawy, AG, MS, MA, MAN. *Critical revision of the manuscript for important intellectual content* was contributed by MR, AMH, and SE. *Statistical analysis* was contributed by SN, MA, MS, MA, and MAN. *Administrative, technical, or material support* were contributed by SN, MR, AMH, and AG. *Supervision* was contributed by MR and SE. All authors read and approved the final manuscript.

Funding

No funding resources.

Competing interests

All authors declare that they have no competing interests.

Consent for publication

A written informed consent was taken from the parents of all patients included in this research to publish the data contained within this study.

Ethics approval and consent to participate

An approval was taken from our local ethical committee. Ethical committee approval number: 30504/09/15. A signed consent was taken from the parents of the children. Patients' confidentiality was kept, and subjects' names were referred to by plotted numbers in the master table.

Author details

¹ Urology Department, Tanta University, Tanta, Egypt. ² Urology Department, Benha University, Benha, Egypt. ³ Pediatric Surgery Unit, Tanta University, Tanta, Egypt. ⁴ Pediatric Surgery Unit, Qena Faculty of Medicine, South Valley University, Qena, Egypt.

Received: 10 January 2020 Accepted: 28 January 2020

Published online: 06 April 2020

References

- Smith ED (1997) The history of hypospadias. *Pediatr Surg Int* 12:81–85
- Lee Olivia T, Durbin-Johnson Blythe, Kurzrock Eric A (2013) Predictors of secondary surgery after hypospadias repair: a population based analysis of 5,000 patients. *J Urol* 190:251–256
- Oswald J, Korner I, Riccabona M (2000) Comparison of the perimeatal-based flap (Mathieu) and the tubularized incised-plate urethroplasty (Snodgrass) in primary distal hypospadias. *BJU Int* 85:725–727
- Yesildag E, Tekant G, Sarimurat N, Buyukunal SN (2004) Do patch procedures prevent complications of the Mathieu technique? *J Urol* 171:2623–2625
- Snodgrass Warren T, Bush Nicol, Cost Nicholas (2009) Algorithm for comprehensive approach to hypospadias reoperation using 3 techniques. *J Urol* 182:2885–2892
- Snodgrass Warren, Cost Nicholas, Nakonezny Paul A, Bush Nicol (2011) Analysis of risk factors for glans dehiscence after tubularized incised plate hypospadias repair. *J Urol* 185:1845–1851
- Ziada AM, Morsi H, Aref A, Elsaied W (2006) Tubularized incised plate (TIP) in previously operated (redo) hypospadias. *J Pediatr Urol* 2(5):409–414
- Barbagli G, Lazzeri M (2007) Surgical treatment of anterior urethral stricture diseases: brief overview. *Int Braz J Urol* 33:461–469

9. Elsayed ER, Khalil S, Abd Samad K, Abdalla MM (2012) Evaluation of distally folded onlay flap in repair of distal penile hypospadias. *J Pediatr Urol* 8(1):103–107
10. Seong HB, Jun NL, Hyun TK, Sung KC (2014) Urethroplasty by use of turnover flaps (modified Mathieu procedure) for distal hypospadias repair in adolescents: comparison with the tubularized incised plate procedure. *Korean J Urol* 55(11):750–755
11. Gianantonio M, Giacinto M (2007) Reoperative hypospadias. *Curr Opin Urol* 17:268–271
12. Minevich E, Pecha BR, Wacksman J, Sheldon CA (1999) Mathieu hypospadias repair: experience in 202 patients. *J Urol* 162:2141–2143
13. Nezami BG, Mahboubi AH, Tanhaevash R, Tourchi A, Kajbafzadeh AM (2010) Hypospadias repair and glans augmentation using a modified Mathieu technique. *Pediatr Surg Int* 26(3):299–303
14. Kiss A, Nyirady P, Pirot L, Merksz M (2013) Combined use of perimeatal-based flap urethroplasty (Mathieu) with midline incision or urethral plate in hypospadias repair. *Eur J Pediatr Surg* 13:383–385
15. Anwar AZM, Hussein A, Shaaban AM, Abdel-Malek M (2015) Modified Mathieu repair for failed surgery for hypospadias: perimeatal-based flap with. A subdermal vascular dartos pedicle. *Afr J Urol* 21:100–104
16. Hakim S, Merguerian PA, Rabinowitz R, Shortliffe LD, McKenna PH (1996) Outcome analysis of the modified Mathieu hypospadias repair: comparison between stented and unstented. *J Urol* 156:836–838
17. Buson H, Samiley D, Reinberg Y, Gonzalez R (1994) Distal hypospadias repair without stents: is it better? *J Urol* 151:59–60
18. Emir L, Erol D (2003) Mathieu urethroplasty as a salvage procedure: 20-year experience. *J Urol* 169:2325–2327
19. Chen JB, Yang TQ, Luo YG, Wang H, Tang XM (2013) Modified Mathieu urethroplasty for failed hypospadias repair. *Zhonghua Nan Ke Xue* 19:923–926
20. Nguyen MT, Snodgrass WT (2004) Tubularized incised plate hypospadias re-operation. *J Urol* 171:2404–2406

Publisher's Note

Springer Nature remains neutral with regard to jurisdictional claims in published maps and institutional affiliations.

Submit your manuscript to a SpringerOpen[®] journal and benefit from:

- Convenient online submission
- Rigorous peer review
- Open access: articles freely available online
- High visibility within the field
- Retaining the copyright to your article

Submit your next manuscript at ► [springeropen.com](https://www.springeropen.com)
